

Differential afferent projections to the inferior colliculus from the cochlear nucleus in the albino mouse

D. K. RYUGO, F. H. WILLARD and D. M. FEKETE

Department of Anatomy, Harvard Medical School, Boston, Mass. 02115, Eaton-Peabody Laboratory, Massachusetts Eye and Ear Infirmary, Boston, Mass. 02114 and (F.H.W.) Department of Anatomy and Neurobiology, University of Vermont College of Medicine, Burlington, Vt. 05401 (U.S.A.)

(Accepted November 6th, 1980)

Key words: auditory pathway — cochlear nucleus — differential projection — topography — inferior colliculus

The axonal projections from the cochlear nuclear complex to the inferior colliculus (IC) were examined using the retrograde transport of horseradish peroxidase. Thin sheets of neurons in the dorsal and ventral cochlear nuclei were found to project axons in a topographic fashion to restricted laminae of the central nucleus of the IC; the dorsal cochlear nucleus was also found to project axons to the external cortex. No projections were detected from the cochlear nuclear complex to the dorsal cortex of the IC.

In mammals, all ascending auditory pathways in the brain are inferred to originate in the cochlear nucleus because no primary fibers of the auditory nerve bypass the nucleus^{13,22,25}. Thus, knowledge of the axonal projections from the cochlear nucleus to higher levels is basic to understanding the organization of the central auditory system. Furthermore, it is important to have such knowledge for a great many species in view of the many different life styles of mammals. It is in this context that we present our observations on the projections of the cochlear nucleus to the inferior colliculus in the mouse.

Both the cochlear nucleus^{3,10–12,16,21,25} and the inferior colliculus^{5,20,25,28,31} are complex structures and each consists of many morphologically distinguishable subdivisions. Neurons with their cell bodies in the two major divisions of the cochlear nucleus, the ventral cochlear nucleus and the dorsal cochlear nucleus, are known to have axonal projections that terminate in the central nucleus of the inferior colliculus^{1,23,27–30}; however, the axonal projections to the other major subdivisions of the inferior colliculus (dorsal cortex and external cortex) have received little attention. In the present study, we used the retrograde transport of horseradish peroxidase (HRP) to determine the location of neurons in the cochlear nucleus that project to each of the major subdivisions of the inferior colliculus.

Unilateral injections of HRP (Sigma, type VI) were made through a glass micropipette⁸ into an exposed inferior colliculus of 15 Swiss albino mice. After an 18–24 h

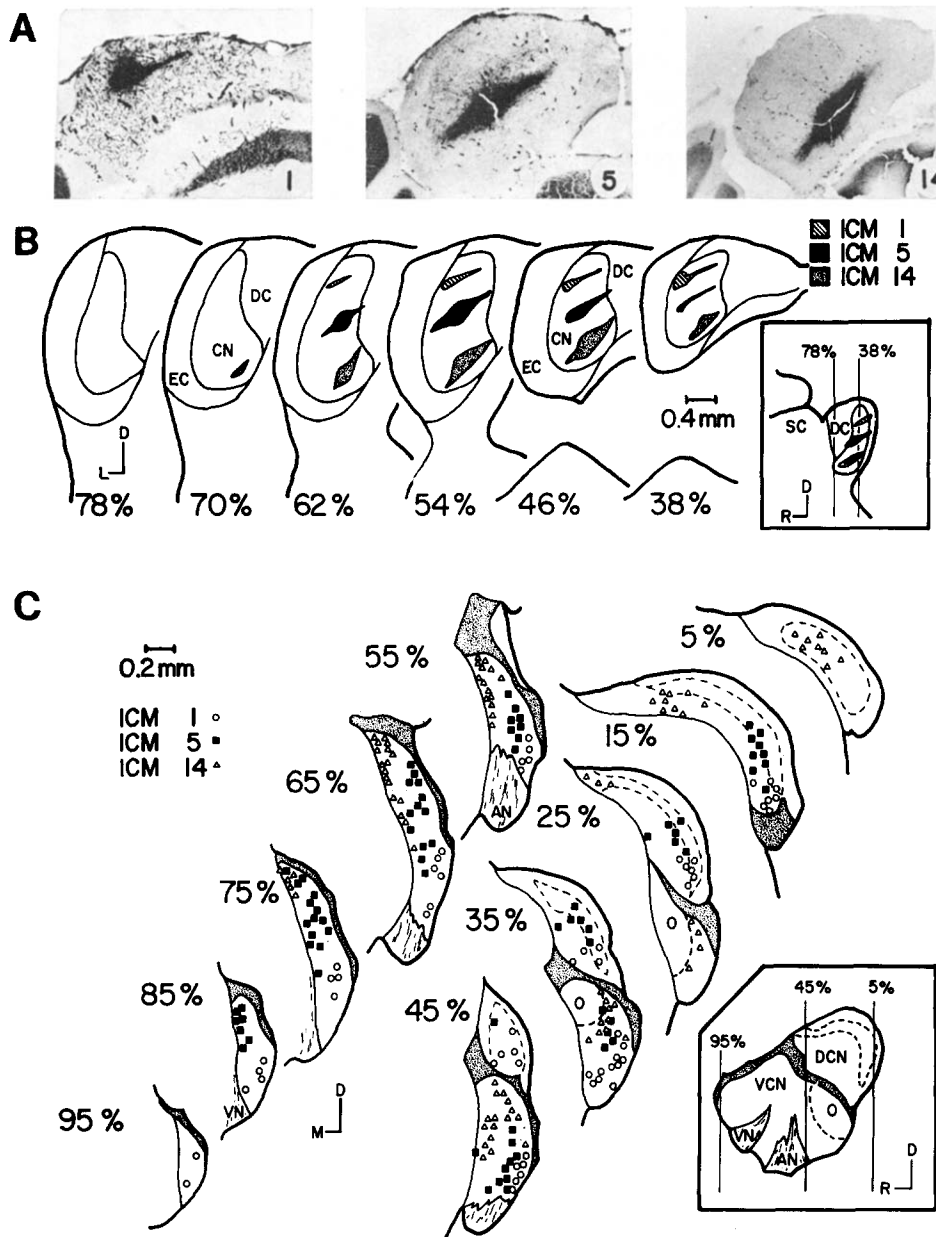


Fig. 1. Topographic relationship between HRP injection site in the central nucleus of the inferior colliculus and the location of HRP-labeled neurons in the contralateral cochlear nucleus. A: photomicrographs of HRP injection sites from 3 separate animals; coronal sections, (left-to-right) ICM-1, ICM-5 and ICM-14. B: schematic illustration of 3 HRP injection sites within the central nucleus. Note the planar shape of each injection site. The percentages represent the relative position of each coronal section along the rostrocaudal axis of the inferior colliculus. Inset: sagittal view of the HRP injection sites through the middle of the central nucleus with corresponding percentages marked by vertical lines. Abbreviations: CN, central nucleus; D, dorsal; DC, dorsal cortex; EC, external cortex; L, lateral; R, rostral; SC, superior colliculus. C: coronal atlas of the cochlear nucleus in 10% intervals illustrating the location of HRP-labeled neurons from animals ICM-1, ICM-5 and ICM-14. Each symbol represents the location of one HRP-labeled neuron, mapped onto its corresponding atlas section. Sheets of HRP-labeled neurons are seen in both VCN and DCN that are topographically related to the laminar organization of the central nucleus. Inset: sagittal view through the middle of the cochlear nucleus with corresponding atlas percentages marked by vertical lines. Abbreviations: AN, auditory nerve; D, dorsal; DCN, dorsal cochlear nucleus; M, medial; O, octopus cell area; R, rostral; VCN, ventral cochlear nucleus; VN, vestibular nerve.

survival, each animal was given a lethal dose of nembutal and immediately perfused transcardially with buffered fixative according to the procedure of Mesulam¹⁷. Serial, coronal, 40 μm frozen sections were collected from the upper cervical spinal cord through the thalamus and mounted on microscope slides; the sections were air dried, reacted with either benzidine dihydrochloride¹⁷ or tetramethyl benzidine¹⁸, and counterstained with neutral red or cresyl violet. All sections through the cochlear nuclear complex and inferior colliculus were drawn at a magnification of 40 \times and assigned to a percentile (calculated by dividing the individual section number by the total number of sections required to traverse the nucleus). Blood vessels and other prominent features were included in the drawings to provide landmarks for the localization and mapping of each injection site and HRP-labeled neuron when viewed through the microscope.

The central nucleus of the mouse inferior colliculus may be distinguished by its cells and their dendrites which tend to be aligned along parallel planes; this morphological arrangement endows the central nucleus with the appearance of stacked laminae, tilted in a dorsomedial-to-ventrolateral orientation. Diffusion of HRP from each injection site within the central nucleus in 6 animals was indicated by HRP reaction product over a disc-shaped region, oriented along the laminar contours (Fig. 1A, B). Each injection resulted in a characteristic pattern of HRP-labeled neurons in the contralateral cochlear nucleus; the neurons are clustered in two narrow sheets, one in the ventral cochlear nucleus and another in the dorsal cochlear nucleus. Both sheets are vertically arrayed along the rostral-caudal dimension of the nucleus. Photomicrographs of this pattern of labeling are presented in Fig. 2. Only 5 out of a combined total of 1471 labeled cochlear nucleus neurons in the 6 animals were found on the side ipsilateral to the HRP injection. The distribution of labeled cells in 3 cases of HRP injections into the central nucleus has been plotted on corresponding atlas sections of the cochlear nucleus at 10% intervals (Fig. 1C). There is a topographic relationship between the HRP injection site in the central nucleus and the position of HRP-labeled cells in the cochlear nucleus (Fig. 1). HRP injections into the dorsal laminae of the central nucleus (ICM-1) produce a sheet of HRP-labeled neurons that extends along the ventrolateral ventral cochlear nucleus and a second sheet that lies in the ventrolateral dorsal cochlear nucleus. HRP injections into more ventral laminae (ICM-5, ICM-14) result in sheets of HRP-labeled cells in both ventral and dorsal cochlear nuclei which are positioned progressively more dorsally and medially.

A cellular rind, composed of the dorsal cortex and external cortex, surrounds the central nucleus of the inferior colliculus^{5,20,25}. HRP injections into the external cortex ($n = 3$, Fig. 3A, B) produced labeling of cells in the cochlear nucleus only on the contralateral side. Nearly all of the cells (120/132) were located in the dorsal cochlear nucleus while the remainder were scattered in the ventrolateral ventral cochlear nucleus (Fig. 3C). One possible interpretation of these findings is that afferents to the external cortex arise from the dorsal cochlear nucleus with the few HRP-labeled neurons in the ventral cochlear nucleus resulting from HRP diffusion away from the external cortex injection site and into the dorsal laminae of the central nucleus (see Fig. 3B). The HRP-labeled neurons in the ventral cochlear nucleus are, in fact, located

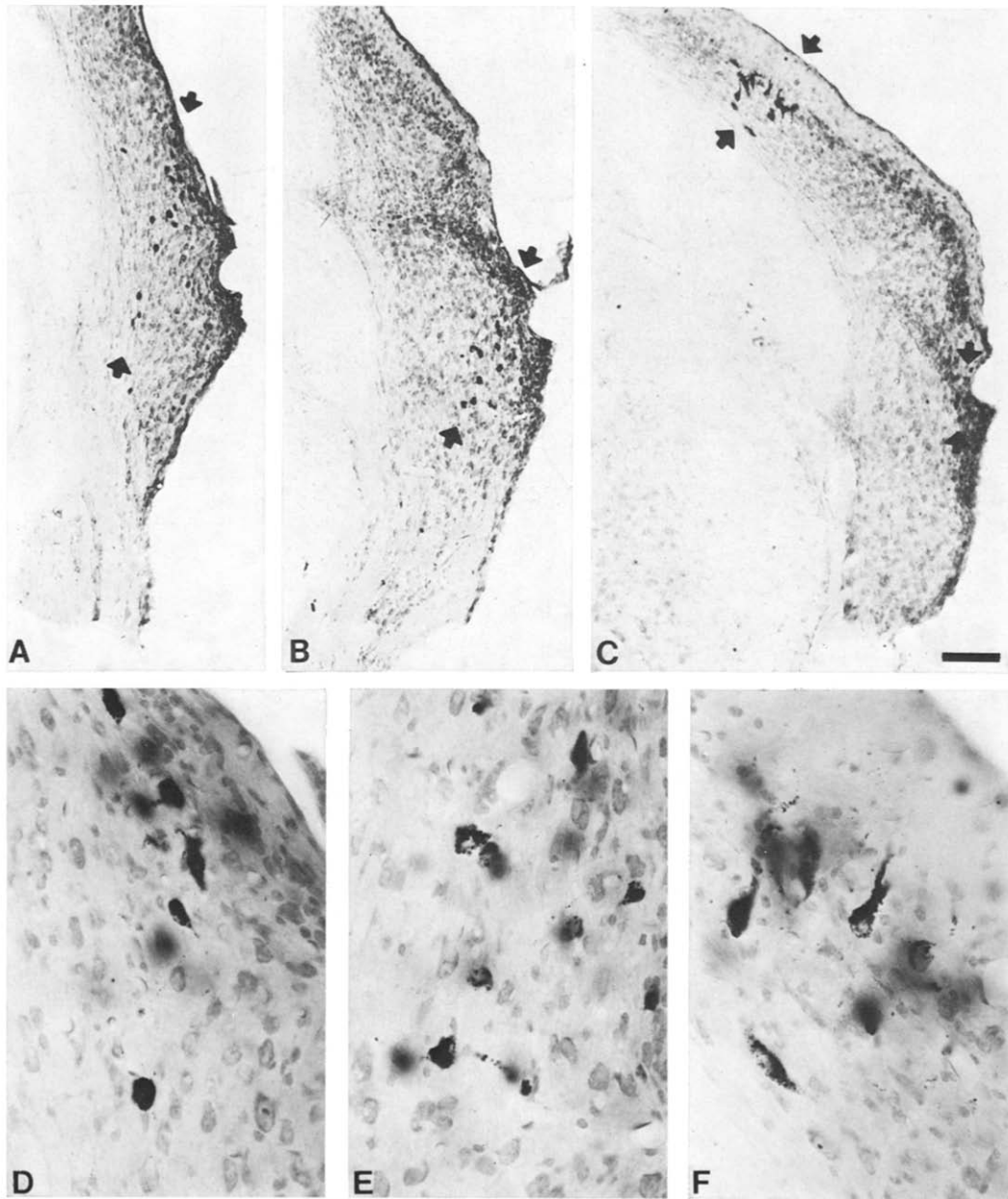


Fig. 2. Photomicrographs of coronal sections through the cochlear nucleus of animal ICM-5. Sections A, B and C correspond respectively to the 70th, 50th and 30th percentile of the cochlear nucleus atlas and illustrate the pattern of HRP-labeled neurons (arrows). Increased magnification of HRP-labeled neurons are shown in D, E and F, corresponding to sections A, B and C. Calibration bar equals 0.1 mm for A, B and C and 25 μ m for D, E and F.

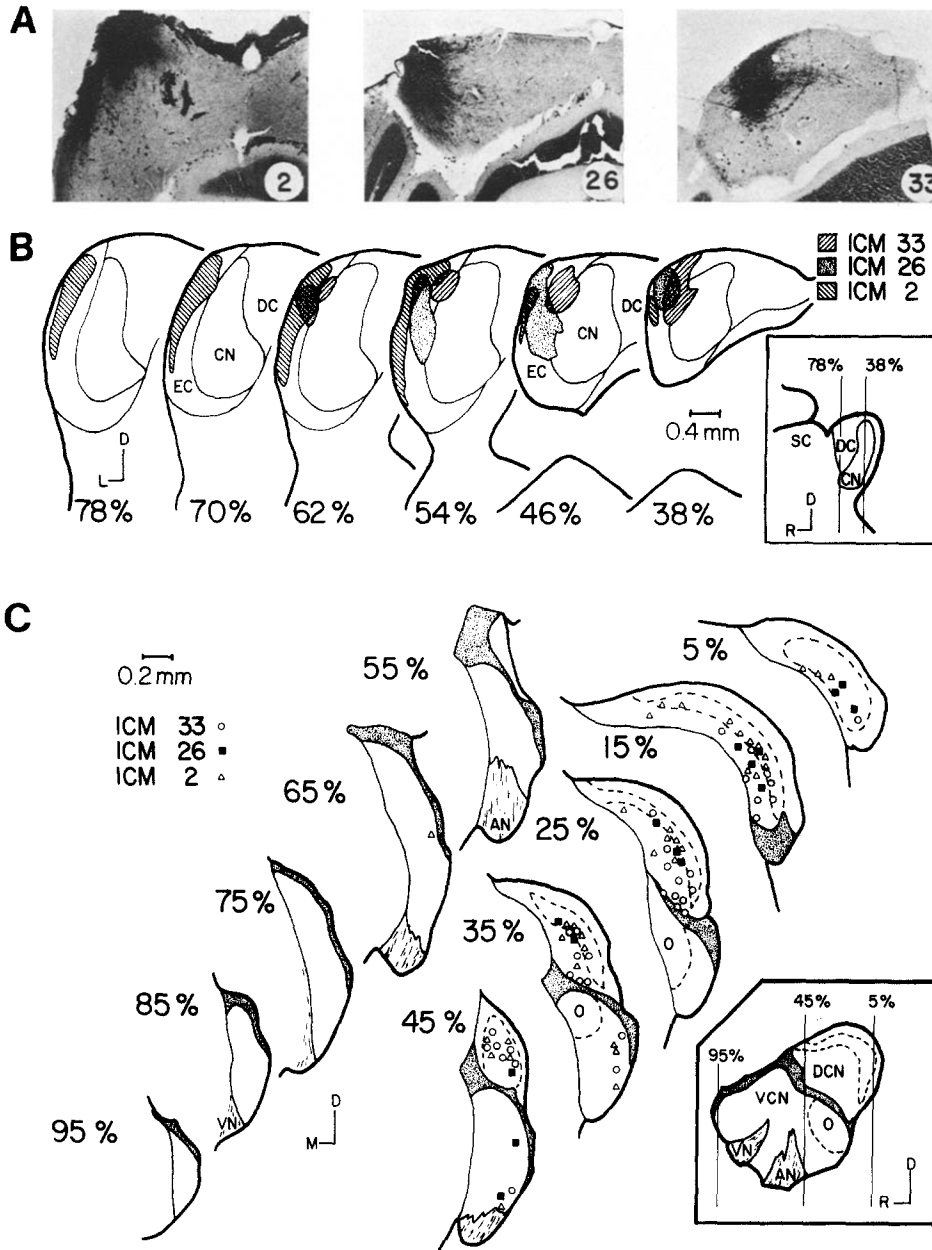


Fig. 3. Apparent topographic relationship between HRP injection site in the external cortex of the inferior colliculus and the location of HRP-labeled neurons in the contralateral cochlear nucleus. **A**: photomicrographs of HRP injection sites from 3 separate animals; coronal sections, (left-to-right) ICM-2, ICM-26, and ICM-33. **B**: schematic illustration of three HRP injection sites within the external cortex of the inferior colliculus. The percentages represent the relative position of each coronal section along the rostro-caudal axis of the inferior colliculus. Inset: sagittal view through the middle of the central nucleus with corresponding percentages marked by vertical lines. **C**: coronal atlas of the cochlear nucleus in 10% intervals, illustrating the pattern of HRP-labeled neurons from animals ICM-2, ICM-26, and ICM-33. Each symbol represents the location of one HRP-labeled neuron mapped onto its corresponding atlas section. A topographic relationship is suggested between the position of labeled DCN neurons and the HRP injection site in the external cortex. The few HRP-labeled neurons in the ventral cochlear nucleus are probably due to diffusion of HRP away from the external cortex injection site and into the dorsal laminae of the central nucleus. Inset: sagittal view through the middle of the cochlear nucleus with corresponding atlas percentages marked by vertical lines. Abbreviations are the same as in Fig. 1.

in much the same position as those found after an HRP injection into dorsal laminae of the central nucleus (compare ICM-1 of Fig. 1C to Fig. 3C). The data also reflect a topographic projection from the dorsal cochlear nucleus to the external cortex. HRP injected into dorsal regions of the external cortex results in labeled cells in the ventrolateral dorsal cochlear nucleus. Injections which invade progressively more ventral regions of the external cortex result in labeled cells positioned in progressively more dorsomedial parts of the dorsal cochlear nucleus. Smaller injections are needed, however, to define this topography unequivocally. Six injections of HRP confined to the dorsal cortex of the inferior colliculus never produced detectable labeled cells in the cochlear nucleus.

In some cases, the HRP-labeled neurons have been compared with cell types defined in other species^{3,21}. In the dorsal cochlear nucleus, only the largest cells are labeled following injections into either the central nucleus or external cortex, and the reaction product fills the cell bodies and proximal dendrites (Fig. 2F). Most of these cells (73%) were found in the granule cell layer (central nucleus injections: 29/36, 18/27, 53/68, 24/27, 45/64, 123/178; external cortex injections: 30/42, 16/26, 51/64) while the remainder were located in the deep polymorphic layer. Comparison of the HRP-labeled neurons with Golgi- and Nissl-stained neurons in the mouse dorsal cochlear nucleus suggests that such large cells correspond to pyramidal (fusiform) and giant cells of the cat^{3,21,25}. The identification of HRP-labeled cells in the ventral cochlear nucleus has proven more difficult because the HRP reaction product usually fills only the cell body and rarely the proximal dendrites, so that the cytological details are obscured without showing the characteristics of the dendritic trees. Many of the labeled perikarya are not obviously distinct from unlabeled ones on the basis of size, shape or position (Fig. 2D, E). Neurons identifiable as granule cells, small cells, globular cells and octopus cells on the basis of somal size, shape, Nissl pattern and position within the nucleus²¹ are not labeled, even after HRP injections into the inferior colliculus so massive that every large neuron in the dorsal cochlear nucleus is labeled (3 cases).

It appears that not all parts of the mouse inferior colliculus receive afferent input from the cochlear nucleus. The central nucleus receives topographic projections from both the ventral and dorsal cochlear nuclei, mainly from the contralateral side. The external cortex apparently receives a topographic projection from the contralateral dorsal cochlear nucleus. The dorsal cortex, however, appears to receive no projections from the cochlear nuclei. We have produced anterograde degeneration of dorsal cochlear nucleus neurons³¹ to confirm the projections to both the central nucleus and the external cortex. In this material, some degenerating axons clearly branched and innervated both regions; again, there was no appreciable projection to the dorsal cortex.

The sheet-like arrangement of cochlear nucleus neurons which project to restricted laminae in the central nucleus corresponded closely to the cochleotopic course and termination of primary afferents^{22,25}, and is consistent with previously reported tonotopic organization^{19,26}. Presumably, the topography of these connections account for, at least in part, the tonotopicity reported for the mouse central

nucleus⁹. The various cell types in the cochlear nuclear complex receive morphologically distinct endings of primary afferent fibers^{16,25} and differ in their projections to the inferior colliculus and other brain stem nuclei²⁸⁻³⁰; it is therefore not surprising that they respond differently to acoustic stimulation^{6,7,14}, react differently to cochlea destruction^{15,24} or anesthesia⁴ and play different roles in acoustic reflexes².

We are grateful to Rebecca C. Schreiber for technical assistance, Peter Ley for photographic assistance, Joan Casey for typing assistance, and to Doctors T. R. Bourk and N.Y-S. Kiang for their helpful comments on the manuscript. This work was supported by NIH Grant NS 13126 and GRS Grant PSH5429-40.

- 1 Beyerl, B. D., Afferent projections to the central nucleus of the inferior colliculus in the rat, *Brain Research*, 145 (1978) 209-233.
- 2 Borg, E., On the neuronal organization of the acoustic middle ear reflex. A physiological and anatomical study, *Brain Research*, 49 (1973) 101-123.
- 3 Brawer, J. R., Morest, D. K. and Kane, E. C., The neuronal architecture of the cochlear nucleus of the cat, *J. comp. Neurol.*, 155 (1974) 251-300.
- 4 Evans, E. F. and Nelson, P. G., The responses of single neurones in the cochlear nucleus of the cat as a function of their location and the anaesthetic state, *Exp. Brain Res.*, 17 (1973) 402-427.
- 5 Geniec, P. and Morest, D. K., The neuronal architecture of the human posterior colliculus, *Acta oto-laryng.*, Suppl. 295 (1971) 1-33.
- 6 Godfrey, D. A., Kiang, N. Y. S. and Norris, B. E., Single unit activity in the dorsal cochlear nucleus of the cat, *J. comp. Neurol.*, 162 (1975) 269-284.
- 7 Goldberg, J. M. and Brownell, W. E., Discharge characteristics of neurons in anteroventral and dorsal cochlear nucleus of cat, *Brain Research*, 64 (1973) 35-54.
- 8 Graybiel, A. M. and Devor, M., A microelectrophoretic delivery technique for use with horseradish peroxidase, *Brain Research*, 68 (1974) 167-173.
- 9 Harnischfeger, G., Single unit study in the inferior colliculus of the house mouse (*mus musculus*), *Neurosci. Lett.*, 9 (1978) 279-284.
- 10 Harrison, J. M. and Irving, R., The anterior ventral cochlear nucleus, *J. comp. Neurol.*, 124 (1965) 15-42.
- 11 Harrison, J. M. and Irving, R., The organization of the posterior ventral cochlear nucleus in the rat, *J. comp. Neurol.*, 126 (1966) 391-402.
- 12 Harrison, J. M. and Warr, W. B., A study of the cochlear nuclei and ascending auditory pathways of the medulla, *J. comp. Neurol.*, 119 (1962) 341-379.
- 13 Jones, D. R. and Casseday, J. H., Auditory nerve: projections from cochlea demonstrated by autoradiographic methods, *Brain Research*, 148 (1978) 224-229.
- 14 Kiang, N. Y. S., Pfeiffer, R. R., Warr, W. B., and Backus, A. S., Stimulus coding in the cochlear nucleus, *Ann. Otol. (St. Louis)*, 74 (1965) 463-485.
- 15 Koerber, K. C., Pfeiffer, R. R., Warr, W. B. and Kiang, N. Y. S., Spontaneous spike discharges from single units in the cochlear nucleus after destruction of the cochlea, *Exp. Neurol.*, 16 (1966) 119-130.
- 16 Lorente de Nó, R., Anatomy of the eighth nerve. III. General plan of structure of the primary cochlear nuclei, *Laryngoscope (St. Louis)*, 43 (1933) 327-350.
- 17 Mesulam, M., The blue reaction product in horseradish peroxidase neurohistochemistry: incubation parameters and visibility, *J. Histochem. Cytochem.*, 24 (1976) 1273-1280.
- 18 Mesulam, M., Tetramethyl benzidine for horseradish peroxidase neurohistochemistry: a noncarcinogenic blue reaction-product with superior sensitivity for visualizing neural afferents and efferents, *J. Histochem. Cytochem.*, 26 (1978) 106-117.
- 19 Mikaelian, D. O., Single unit study of the cochlear nucleus in the mouse, *Acta. oto-laryngol. (Stokh.)*, 62 (1966) 545-556.
- 20 Oliver, D. L. and Hall, W. C., The medial geniculate body of the tree shrew, *Tupaia glis*: I. Cytoarchitecture and midbrain connections, *J. comp. Neurol.*, 182 (1978) 423-458.
- 21 Osen, K. K., Cytoarchitecture of the cochlear nuclei of the cat, *J. comp. Neurol.*, 136 (1969) 453-484.

- 22 Osen, K. K., Course and termination of the primary afferents in the cochlear nuclei of the cat, *Arch. ital. Biol.*, 108 (1970) 21–51.
- 23 Osen, K. K., Projection of the cochlear nuclei on the inferior colliculus in the cat, *J. comp. Neurol.*, 144 (1972) 355–372.
- 24 Powell, T. P. S. and Erulkar, S. D., Transneuronal cell degeneration in the auditory relay nuclei of the cat, *J. Anat. (Lond.)*, 96 (1962) 249–268.
- 25 Ramón y Cajal, S., *Histologie du Systeme Nerveux de L'Homme et des Vertebres, Vol. 1*, Maloine, Paris, 1909.
- 26 Rose, J. E., Organization of frequency sensitive neurons in the cochlear nucleus complex of the cat. In G. L. Rasmussen and W. F. Windle (Eds.), *Neural Mechanisms of the Auditory and Vestibular Systems*, Charles C. Thomas, Springfield, Ill., 1960, pp. 116–136.
- 27 Roth, G. L., Aitkin, L. M., Andersen, R. A. and Merzenich, M. M., Some features of the spatial organization of the central nucleus of the inferior colliculus of the cat, *J. comp. Neurol.*, 182 (1978) 661–680.
- 28 Van Noort, J., *The Structure and Connections of the Inferior Colliculus. An Investigation of the Lower Auditory System*, Van Gorcum, Leiden, 1969.
- 29 Warr, W. B., Fiber degeneration following lesions in the anterior ventral cochlear nucleus of the cat, *Exp. Neurol.*, 14 (1966) 453–474.
- 30 Warr, W. B., Fiber degeneration following lesions in the posteroventral cochlear nucleus of the cat, *Exp. Neurol.*, 23 (1969) 140–155.
- 31 Willard, F. H. and Ryugo, D. K., External nucleus of the inferior colliculus: a site of overlap for ascending auditory and somatosensory projections in the mouse, *Neurosci. Abstr.*, 5 (1979) 33.